

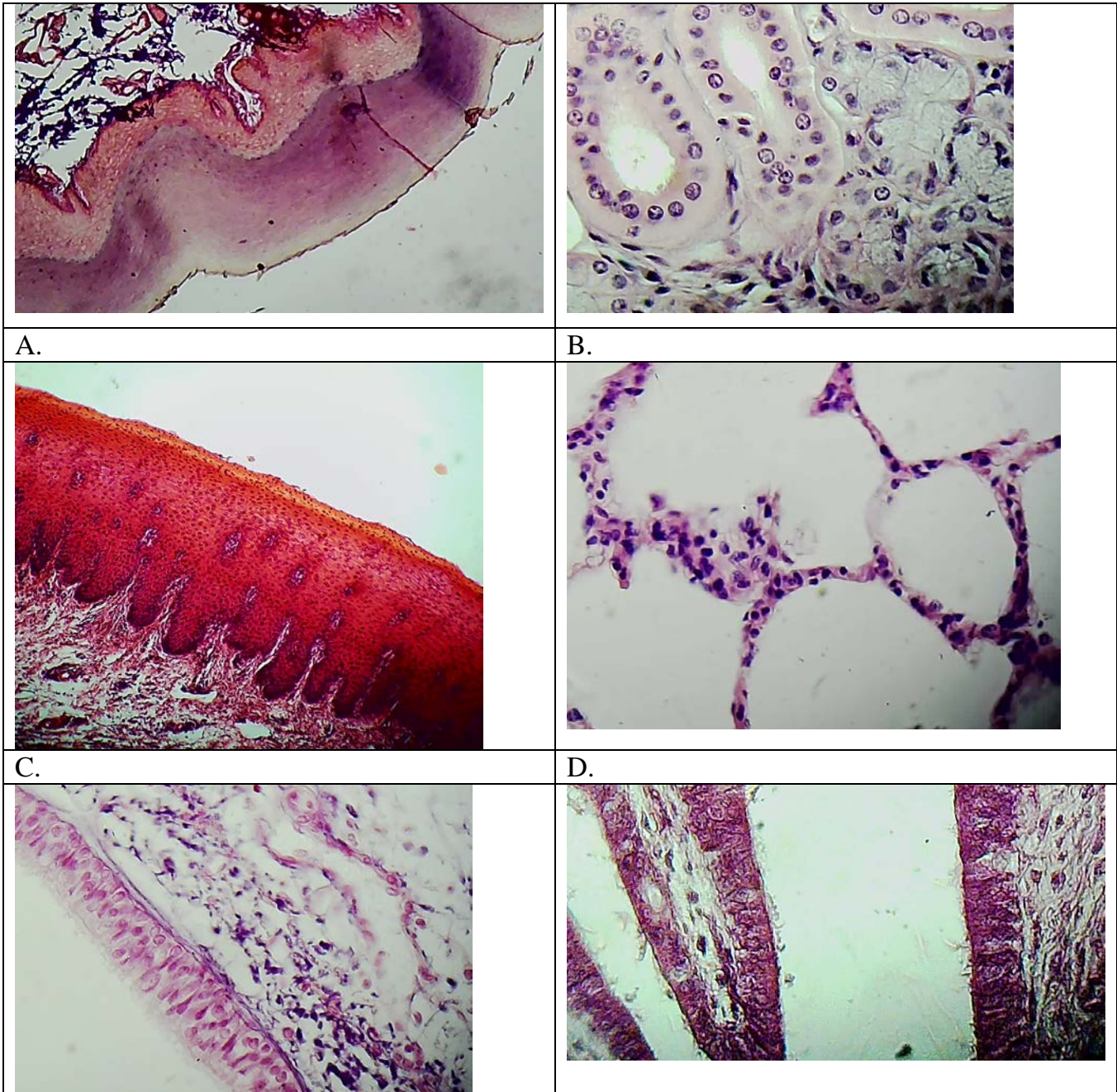
## Unit 2: Tissues

### Lesson 13: *General Review before the Final Test*

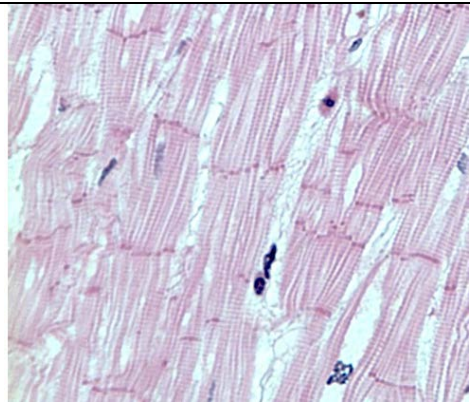
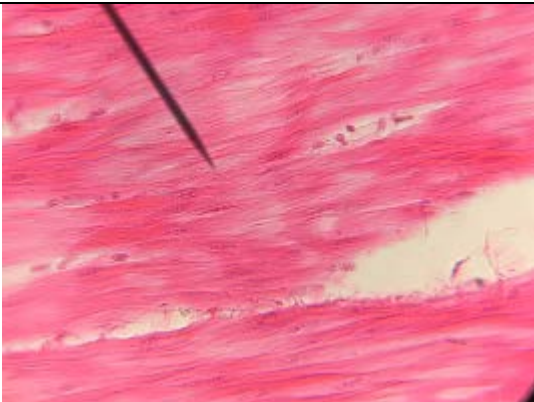
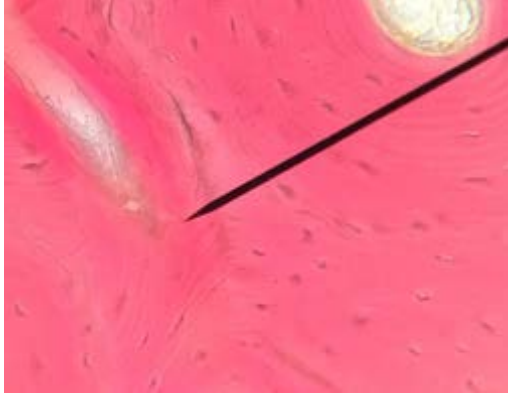
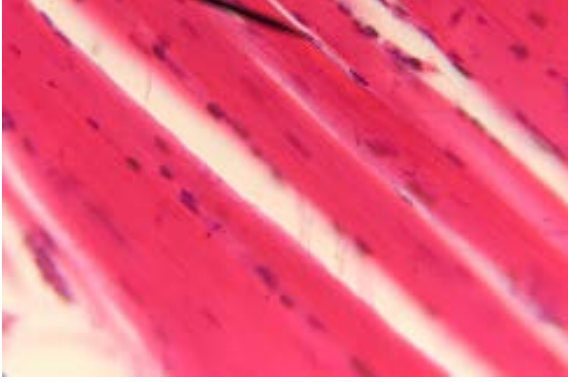
#### Activity 1 (10'): Slides

*In pairs, match each image with the following terms:*

Simple columnar - Non cornified - Simple squamous – Compact bone- Striated muscle-  
Pseudostratified Smooth muscle- -Simple cuboidal- Cardiac- Cornified epithelium



Unit 2- Lesson 13- General Review before the Final Test

<p>E.</p> 	<p>F.</p> 
<p>G.</p> 	<p>H.</p> 
<p>I.</p>	<p>L.</p>

Photos taken by the author. Photo E taken by "<http://www.istologia.unige.it/page13/page2/>"

**Activity 2 (40'):** Concept Map

*In pairs, fill in the missing information in the map*